



Efficacy of topical imiquimod 3.75% in the treatment of actinic keratosis of the scalp in immunosuppressed patients: our case series

E. Zavattaro, F. Veronese, G. Landucci, V. Tarantino & P. Savoia

To cite this article: E. Zavattaro, F. Veronese, G. Landucci, V. Tarantino & P. Savoia (2020) Efficacy of topical imiquimod 3.75% in the treatment of actinic keratosis of the scalp in immunosuppressed patients: our case series, Journal of Dermatological Treatment, 31:3, 285-289, DOI: [10.1080/09546634.2019.1590524](https://doi.org/10.1080/09546634.2019.1590524)

To link to this article: <https://doi.org/10.1080/09546634.2019.1590524>



© 2019 The Author(s). Published with license by Taylor & Francis Group, LLC



Published online: 19 Mar 2019.



Submit your article to this journal [↗](#)



Article views: 711



View related articles [↗](#)



View Crossmark data [↗](#)



Citing articles: 1 View citing articles [↗](#)

Efficacy of topical imiquimod 3.75% in the treatment of actinic keratosis of the scalp in immunosuppressed patients: our case series

E. Zavattaro^{a*}, F. Veronese^{b*} , G. Landucci^b, V. Tarantino^b and P. Savoia^b

^aDepartment of Translational Medicine, University of Eastern Piedmont, Novara, Italy; ^bDepartment of Health Science, University of Eastern Piedmont, Novara, Italy

ABSTRACT

Background: Actinic keratoses (AK) represent common cutaneous lesions, appearing in ‘field cancerization areas’ and potentially evolving toward invasive neoplasm. Immunosuppressed patients frequently develop numerous and aggressive AKs.

Aim: In this observational study, we report our experience with topical Imiquimod 3.75% as ‘field-directed therapy’ in a cohort of immunosuppressed patients.

Methods: A group of 13 immunosuppressed patients presenting multiple AKs of the balding scalp was treated with topical Imiquimod 3.75%. Each patient underwent clinical examination at fixed timepoints during the treatment (T0, T14, T28, T42) and eight weeks after the end.

Results: In our cohort, the treatment was well tolerated, with minimal local adverse events. We observed a good clinical response, in terms of Lmax lesions (maximum lesion count during the course of therapy) and of AK clearance. In our group, 46% of patients showed no detectable lesions at the end of the observation period, and this result was maintained up to 1 year after the end of treatment.

Conclusion: Topical Imiquimod 3.75% represents an effective and safe treatment for multiple AK of the scalp also in immunosuppressed patients. To the best of our knowledge, this is the first report on the use of this drug in this category of subjects.

ARTICLE HISTORY

Received 27 October 2018
Accepted 3 February 2019

KEYWORDS

Actinic keratosis;
immunosuppression; field
cancerization

Introduction

Nonmelanoma skin cancers (NMSCs) represent the most frequent neoplasms in Caucasian subjects. In this group, various clinical entities are included; among them, actinic keratoses (AKs) are one of the most common, thus representing more than 20% of the diagnoses in the Dermatology Outpatient settings (1). They can be observed predominantly in fair-skinned individuals in sun-exposed areas, and their number increases with age. The term ‘Skin Cancerization Field’ is commonly used to indicate areas of chronically UV-damaged skin, where, from a histological point of view, there is a large number of atypical keratinocytes, with the potential to progress to ‘*in situ*’ carcinoma or invasive and metastasizing malignancy (Squamous Cell Carcinoma = SCC) (2,3). Clinical examination of these cutaneous areas reveals the presence of hypo/hyperpigmentation, atrophy, erythema, and of AKs in different grades of differentiation.

Main risk factors for the development of NMSCs are represented by light skin, older age, beta-HPV infection, or immunosuppression, but, currently, UV-radiation exposure and its effect at a molecular level are considered as the major factors related to the development of this neoplasm.

In Italy, as recently reported, the prevalence of AKs is of 27.4%, typically increasing in elderly patients (Odds Ratio 4.8 in people aging 46–60 years; OR 41.5 in subjects >70 years) (4).

Immunosuppression is another important risk factor, and this is further confirmed by the high incidence of AKs in organ transplanted recipients (OTRs), reaching up to 250-fold higher than in immunocompetent subjects (5).

Moreover, due to the immunosuppressive status and in consideration of the photosensitivity of some immunosuppressant drugs, multiple and relapsing AKs are often detectable in OTRs, with a consequent high risk of development of Non-Melanoma Skin Cancer (6–9).

In recent years, the field cancerization concept has reached even more importance, thus leading to the need of its treatment in order to eradicate subclinical lesions, in contrast to the therapy of every single visible lesion (‘lesion-directed’ therapy) (2,3,7).

Imiquimod (IMI) is an agonist of toll-like receptors 7 and 8 for topical use, able to stimulate the cutaneous immune response (10). In Italy, it was approved at the concentration of 5% for the treatment of *condylomata acuminata* and basal cell carcinomas; more recently, IMI 3.75% cream has also been approved in the field therapy of AKs, in sun-exposed areas such as the face or the balding scalp (11). In immunocompetent patients, its clinical effect consists in the detection and clearing of subclinical lesions, which become visible during treatment. On this basis, the concept of Lmax is used to define the maximum lesion count during the course of therapy (12,13).

CONTACT F. Veronese  federica.veronese@med.uniupo.it  Department of Health Science, University of Eastern Piedmont, Via Solaroli 17, 28100 Novara, Italy
*These authors contributed equally to the present work.

© 2019 The Author(s). Published with license by Taylor & Francis Group, LLC

This is an Open Access article distributed under the terms of the Creative Commons Attribution-NonCommercial-NoDerivatives License (<http://creativecommons.org/licenses/by-nc-nd/4.0/>), which permits non-commercial re-use, distribution, and reproduction in any medium, provided the original work is properly cited, and is not altered, transformed, or built upon in any way.

In the present study, we report our experience concerning the treatment of AKs of the scalp with topical IMI 3.75% in a cohort of immunosuppressed patients.

Patients and methods

We consecutively enrolled a group of immunosuppressed patients affected by AKs of the scalp, among those referred to Outpatients Clinic in the Dermatology Unit of the University Hospital of Novara, Italy. The inclusion criteria for the study consisted in: (i) immunosuppression status (OTRs or subjects previously submitted to long-term chemotherapy for neoplasia) (ii) age 18 years or older; (iii) the presence of multiple AKs of the scalp (≥ 3 clinically visible lesions), thus requiring a 'Field Cancerization' treatment; iv) capability to understand the correct use and to self-administer the therapy with IMI 3.75%.

Patients presenting hyperkeratotic lesions requiring surgical excision and/or not able/available to use the prescribed therapy were excluded.

The treatment modalities have been explained to each enrolled patient: 250 mg of cream containing IMI 3.75% has been applied on the affected area (scalp), ranging between 50 and 100 cm², every day for 14 days (first cycle), then the same treatment was repeated (second cycle) after two weeks of rest. Simultaneously, the local and expected effects of the therapy (erythema, exudate, scabbing/crusting, skin erosion or ulceration) and how to manage the skin reactions were clearly explained. Patients underwent to clinical examination before starting the therapy (baseline, T0) and then at fixed time-points: at the end of the first cycle (T14), before and after the second cycle (T28 and T42, respectively) and 8 weeks after the end of the treatment; we calculate Lmax for each patient during treatment. At the 8 weeks' time point, all residual AKs were treated with cryotherapy, in order to obtain the complete clearance of the cancerization field. Subsequently, each patient underwent to periodic follow-up visits, whose frequency (varying from 3 to 6 months) was established either on the basis of clinical response to IMI 3.75% or to patient clinical history (i.e. previous NMSCs or the presence of other suspicious cutaneous lesions). All lesions were counted at baseline and at every clinical examination; clinical photography of the treated site was taken.

Table 1. Patient characteristics.

Patient	Gender	Age	Transplanted organ, date	Immunosuppressive therapy ^a	Cause of Organ failure/Comorbidities	Previous Skin Cancer ^b
1	M	50	Kidney, 2008 ^c	b (previously ael)	Kidney tuberculosis	Multiple NMSCs
2	M	72	Kidney, 2018	ael	Polycystic kidney disease	Multiple AKs
3	M	71	Kidney, 2005	ab	Polycystic kidney disease /MGUS ^d	Multiple NMSCs
4	M	77	Kidney, 2004	ael	Polycystic kidney disease	Multiple NMSCs
5	M	58	Kidney, 2007	al (previously ael)	Hypertensive kidney failure/Multiple myeloma	Multiple NMSCs
6	M	77	Kidney, 1999	ael	Kidney failure of uncertain origin	Multiple NMSCs
7	M	66	Kidney, 2013	ael	Focal glomerulonephritis	Multiple AKs
8	M	80	Kidney, 2005	al	Kidney failure of uncertain origin	Multiple NMSCs
9	M	77	Liver, 2003	al	HCV-related cirrhosis, HCC ^d	Multiple AKs
10	M	71	Liver, 2009	bl (previously al)	HBV-related cirrhosis /Ocular melanoma	Multiple NMSCs
11	M	72	Liver, 2004	dl	HBV-related cirrhosis	Multiple NMSCs
12	M	66	–	VTD, then	Multiple myeloma Multiple sclerosis	Multiple NMSCs
13	M	49	ASCT MEL ^e – beta IFN (2011) ^e	ABVD + RT	Stage 2 Hodgkin lymphoma	Multiple NMSCs

^aImmunosuppressive therapy: a: tacrolimus; b: mTORinhibitor; d: Cyclosporin; e: Mofetil Mychophenolate; f: azatioprin; l: steroid.

^bNMSC: Nonmelanoma skin cancer; AK: actinic keratosis.

^cPatient returned to hemodialysis 3 months before Imiquimod therapy.

^dMGUS: Monoclonal Gammopathy of Undetermined Significance; HCC: Hepatocellular carcinoma.

^eVTD: Bortezomid–Talidomide–Dexamethasone; ASCT: autologous stem cell transplant; MEL: melphalan; ABVD: Adriamycin-Bleomycin-Vinblastine-Dacarbazine; RT: radiotherapy; beta IFN: beta Interferon.

The present study has been conducted in accordance with Good Clinical Practice, the principles of the Declaration of Helsinki and all relevant local regulations.

Results

A total of 13 immunosuppressed patients were enrolled in the present study; all were males, with a mean age of 68.1 years at the time of the treatment (range 49–80 years). Eleven subjects were OTRs: in detail 8 patients had previously undergone kidney and three liver transplantation; mean transplant duration was 11.2 years (range 6 months–19 years). The remaining two patients from our cohort previously received chemotherapy (and/or radiotherapy) for hematological neoplasms; one patient had also been submitted to autologous stem cell transplantation. All the enrolled patients had been previously affected by multiple NMSCs that required different treatments, thus including cryotherapy, topical therapy (i.e. diclofenac sodium 3% or ingenol mebutate) and/or surgery. The clinical data of patients, including immunosuppressive therapy, the cause of organ failure or other comorbidities are summarized in Table 1.

At baseline, the median number of clinically evident lesions was 8 (range 3–30); at the end of the first cycle (T14, timepoint that in all patients corresponded to the Lmax) it was 14 (range

Table 2. Number of detectable lesions for each patient at different timepoints.

Patient	Number of detectable lesions				
	T0	T14 Lmax	T28	T42	Follow-up (8 weeks)
1	19	26	9	9	4
2	30	45	13	15	7
3	12	14	7	7	0
4	10	22	9	12	4
5	6	12	4	10	0
6	15	25	10	13	8
7	8	10	5	7	3
8	8	14	7	8	4
9	8	10	6	8	3
10	3	4	2	2	0
11	4	8	3	2	0
12	16	30	5	7	0
13	3	6	4	5	0
Median no of AKs	8	14	9	8	3

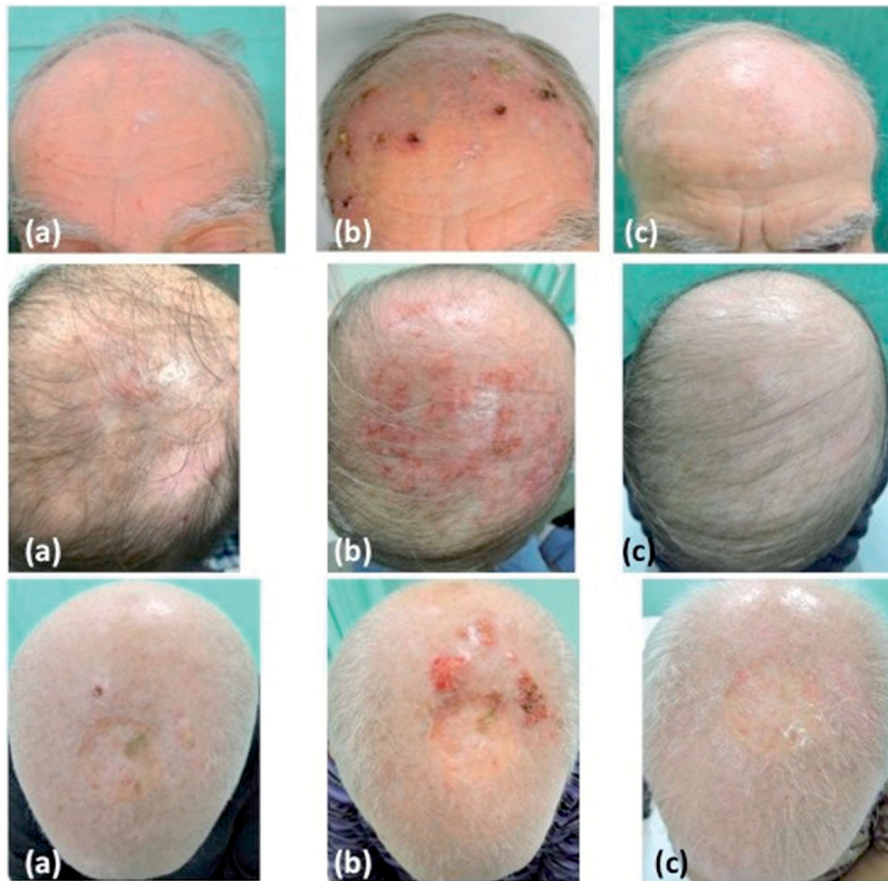


Figure 1. Clinical images of a group of patients at different timepoints corresponding to (a) T0, (b) T14, end of first cycle of treatment (L max) and (c) follow up 8 weeks after the end of therapy.

4–45). The median number of AKs at T28 was 9 and at T42 was 8. After 8 weeks of follow-up, the median number of lesions was 3; in detail, 6/13 patients (46%) achieved the complete clearance of the lesions (no AKs detectable), 5/13 (38%) had a 50% reduction and 2/13 (16) had a reduction of about 80% in the number of the lesions previously observed (Table 2). At the current time, all patients (both those treated with imiquimod alone and those treated with cryotherapy of residual lesions) show complete remission of the treated area after a median follow-up of 6 months (range 3–12 months).

Representative clinical images of our patients are reported in Figure 1. Lesion count expressed as median at different time points is reported in the graph in Figure 2.

All patients of our cohort completed the treatment, and no severe adverse effects occurred; only one patient complained of asthenia and mild fatigue during the first cycle of therapy that promptly disappeared during the rest period. In no patient, we have observed abnormalities in routine blood tests nor alterations in serum immunosuppressant level during the course of treatment, and no signs of local infections were displayed. Local skin reaction occurred mainly during the first cycle of therapy. Patients were trained to apply wet dress with a Saline solution (0.9% sodium chloride) in the treated site twice daily, hence, only in two cases with a severe reaction, the use of topical antibiotics for a few days was required. Any patient reported pain related to the therapy, only a mild itching was felt in the course of skin reaction, mainly after the first cycle of therapy (Lmax timepoint). The local reactions and their severity for each patient are reported in Table 3.

Discussion

In the present study, we report our experience with topical Imiquimod 3.75% for the treatment of AKs of the balding scalp in a cohort of immunosuppressed patients. To the best of our knowledge, this is the first study evaluating the efficacy and tolerability of this Imiquimod concentration in OTRs and/or in immunosuppressed patients (so far, in literature, only the use of IMI 5% has been reported). Our results confirmed the good efficacy of IMI 3.75% also in this category of subjects, without significant differences in local skin reactions and/or drug adverse effects with respect to immunocompetent individuals (12–13). Another important point to be underlined was, in our case series, the lack of interactions between IMI 3.75% and immunosuppressive therapy, similar to what reported for IMI 5%.

The fact that OTRs have a higher prevalence of AKs and significant risk to develop NMSCs (namely invasive SCCs), compared to the immunocompetent subjects supports the high need for a proper treatment of the cancerization field, thus including the chance to clear also the subclinical lesions. On this basis, while the 5% IMI must be applied exclusively to single lesions, IMI 3.75% has to be used on the whole cancerization field, thus leading to detect, reveal and destroy subclinical lesions, that represent the expression of keratinocyte damage prone to neoplastic transformation within a short time. So, treating the field cancerization would allow preventing the appearance of further AKs and potentially invasive SCCs. However, further scientific studies are needed in order to compare the efficacy of IMI 3.75% with other therapies currently recommended in AKs and Cancerization Field,

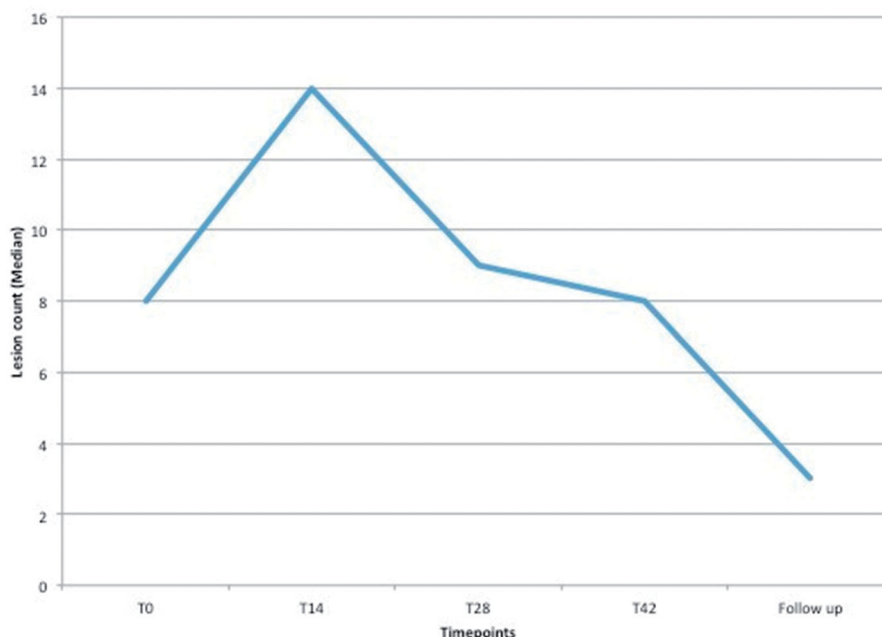


Figure 2. Graph showing the lesion counts expressed as median value of all the patients at different examined timepoints.

Table 3. Severity of local reactions.

Local reactions			
Patient	T14	T42	Follow-up (8 weeks)
1	moderate	mild	resolved
2	severe	mild	resolved
3	mild	mild	resolved
4	moderate	mild	resolved
5	mild	moderate	resolved
6	moderate	mild	resolved
7	mild	mild	resolved
8	mild	mild	resolved
9	mild	mild	resolved
10	mild	mild	resolved
11	mild	mild	resolved
12	severe	mild	resolved
13	mild	mild	resolved

Mild: erythema; Moderate: erythema, crusts; Severe: erythema, edema, crusts and serum.

especially in the setting represented by OTRs and immunosuppressed patients.

In literature, several guidelines for the treatment of actinic keratosis are currently available, often showing differences between various countries (14,15); recently, Richard and coll. published a review on the management of AKs in high-risk patients. In this latter category, OTRs, as well as subjects suffering from hematological neoplasms (i.e. chronic lymphocytic leukemia) are included, and the authors recommend an early treatment of the lesions, through the use of Photodynamic Therapy (PDT), laser ablation and/or curettage and surgery, together with a regular and strict follow-up (16).

However, best treatments in these high-risk patients are represented by the 'Field-directed therapies', that means those treatments able not only to eradicate visible lesions but also to allow a complete clearance of the cancerization field.

About this, there are data supporting the use of PDT in the treatment of AKs in OTRs; and a recent clinical trial compares PDT with IMI 5%, showing a higher efficacy of PDT (17,18). In a recent review, PDT shows the highest rates of complete clearance

(40–76.4%), followed by IMI 5% (27.5–62.1%), diclofenac (41%) and 5-Fluorouracil (11%), in OTRs (19).

The use of Imiquimod in OTRs is still controversial and it is not allowed worldwide: in fact, the European Medicines Agency advises the cutaneous treatment in OTRs only for areas smaller than 60 cm², unless this cutoff is related to the concentration of 5% (20). The use of this molecule was initially limited due to the potential role of the immune system activators in inducing graft rejection. Indeed, the only major adverse event reported in OTRs treated with IMI is represented by a case of acute tubular necrosis in a kidney transplant patient, who receive Imiquimod 5% cream for diffuse viral warts. However, the total size of the treated area is not reported, and the effect displayed more than 40 days after the beginning of therapy (21). On the other hand, there are several reports about the use of Imiquimod 5% as safety and successful treatment for actinic keratosis in OTRs (22–24). In any case, all patients included in these studies were treated with IMI at higher concentrations (5%) and for longer periods than in our case series.

To date, studies reporting the use of IMI 3.75% against AKs have highlighted a good efficacy of the treatment together with the scarcity of adverse events, even if there are no reports on OTRs (13,25).

Even if our study is limited by the small number of subjects and by the evaluation conducted only clinically, our experience highlights the efficacy and safety of this therapy, together with good results at subsequent follow-up controls, a distance of up to 1 year also in OTR. We are aware that further studies involving large cohorts of OTRs and instrumental evaluation (i.e. confocal microscopy) are needed, but we believe that this is a relevant contribution in order to stress the need for a complete treatment of the Field Cancerization in immunosuppressed patients.

Acknowledgements

The authors wish to thank all the patients that participate to the present study.

Funding

This work is a part of a project supported by Ministero della Salute – Ricerca Sanatoria Finalizzata [RF-2011-02347779 to PS and EZ].

ORCID

F. Veronese  <http://orcid.org/0000-0001-6438-5171>

References

- Ferrándiz-Pulido C, Lera-Imbuluzqueta M, Ferrándiz C, et al. Prevalence of actinic keratosis in different regions of Spain: the EPIQA Study. *Actas Dermosifilogr*. 2018;109:83–86.
- Figueras Nart I, Cerio R, Dirschka T, et al. Defining the actinic keratosis field: a literature review and discussion. *J Eur Acad Dermatol Venereol*. 2018;32:544–563.
- Stockfleth E. The importance of treating the field in actinic keratosis. *J Eur Acad Dermatol Venereol*. 2017;31:8–11.
- Fargnoli MC, Altomare G, Benati E. Prevalence and risk factors of actinic keratosis in patients attending Italian dermatology clinics. *Eur J Dermatol*. 2017;27:599–608.
- Stockfleth E. Actinic keratoses. In: Stockfleth E, Ulrich C, editors. *Skin cancer after organ transplantation*. Berlin (Germany): Springer; 2009. p. 227–239.
- Tessari G, Naldi L, Boschiero L, et al. Incidence and clinical predictors of a subsequent nonmelanoma skin cancer in solid organ transplant recipients with a first nonmelanoma skin cancer: a multicentre cohort study. *Arch Dermatol*. 2010;146:294–299.
- Wallingford SC, Russell SA, Vail A, et al. Actinic keratoses, actinic field change and associations with squamous cell carcinoma in renal transplant recipients in Manchester, UK. *Acta Derm Venereol*. 2015;95:830–834.
- Kaufmann RA, Oberholzer PA, Cazzaniga S, et al. Epithelial skin cancers after kidney transplantation: a retrospective single-centre study of 376 recipients. *Eur J Dermatol*. 2016;26:265–270.
- Campos GR, Boin I, Campos ID, Junior, et al. Study of factors affecting the incidence of skin cancer in patients after liver transplant. *An Bras Dermatol*. 2017;92:492–498.
- Gaspari AA. Mechanism of action and other potential roles of an immune response modifier. *Cutis*. 2007;79:s36–s45.
- AIFA Authorization EU/1/12/783/001-003. 2017. Available at: https://farmaci.agenziafarmaco.gov.it/aifa/servlet/PdfDownloadServlet?pdfFileName=footer_002560-043585-RCP.pdf
- Stockfleth E, Gupta G, Peris K, et al. Reduction in lesions from Lmax: a new concept for assessing efficacy of field-directed therapy for actinic keratosis. Results with imiquimod 3.75%. *Eur J Dermatol*. 2014;24:23–27.
- Tambone S, Fargnoli MC, Capizzi R, et al. Clinical experience of imiquimod 3.75% for actinic keratosis: results from a case series. *G Ital Derm Venereol*. 2018;153:333–337.
- Peris K, Calzavara-Pinton PG, Neri L, et al. Italian expert consensus for the management of actinic keratosis in immunocompetent patients. *J Eur Acad Dermatol Venereol*. 2016;30:1077–1084.
- Fleming P, Zhou S, Bobotsis R, et al. Comparison of the treatment guidelines for actinic keratosis: a critical appraisal and review. *J Cutan Med Surg*. 2017;21:408–417.
- Richard MA, Amici JM, Basset-Seguín N, et al. Management of actinic keratosis at specific body sites in patients at high risk of carcinoma lesions: expert consensus from the AKTeam™ of expert clinicians. *J Eur Acad Dermatol Venereol*. 2018;32:339–346.
- Basset-Seguín N, Baumann Conzett K, Gerritsen MJP, et al. Photodynamic therapy for actinic keratosis in organ transplant patients. *J Eur Acad Dermatol Venereol*. 2013;27:57–66.
- Trogsverd-Bo K, Halldin C, Sandberg C, et al. Photodynamic therapy is more effective than imiquimod for actinic keratosis in organ transplant recipients: a randomized intraindividual controlled trial. *Br J Dermatol*. 2017;178:903–909.
- Heppt MV, Steeb T, Niesert AC, et al. Local interventions for actinic keratosis in organ transplant recipients: a systematic review. *Br J Dermatol*. 2019;180:43–50. Epub 2018 Oct 31.
- EMA Authorization EU/1/98/080/001-002. 2017. Available at: www.ema.europa.eu/docs/en_GB/document_library/EPAR_-_Product_Information/human/000179/WC500023122.pdf
- Santos-Juanes J, Esteve A, Mas-Vidal A, et al. Acute renal failure caused by imiquimod 5% cream in a renal transplant patient: review of the literature on side effects of imiquimod. *Dermatology*. 2011;222:109–112.
- Ulrich C, Busch JO, Meyer T, et al. Successful treatment of multiple actinic keratoses in organ transplant patients with topical 5% imiquimod: a case report. *Br J Dermatol*. 2006;155:451–454.
- Ulrich C, Bichel J, Euvrard S, et al. Topical immunomodulation under systemic immunosuppression: results of a multicenter, randomized, placebo-controlled safety and efficacy study of imiquimod 5% cream for the treatment of actinic keratoses in kidney, heart, and liver transplant patients. *Br J Dermatol*. 2007;157:25–31.
- Trakatelli M, Katsanos G, Ulrich C, et al. Efforts to counteract locally the effects of systemic immunosuppression: a review on the use of imiquimod, a topical immunostimulator in organ transplant recipients. *Int J Immunopathol Pharmacol*. 2010;23:387–396.
- Swanson N, Abramovits W, Berman B, et al. Imiquimod 2.5% and 3.75% for the treatment of actinic keratoses: results of two placebo-controlled studies of daily application to the face and balding scalp for two-week cycles. *J Am Acad Dermatol*. 2010;62:582–590.