

Transsphenoidal surgery for pituitary adenomas: early results from a single center

**I. Karamouzis, M. Caputo, C. Mele,
A. Nuzzo, M. Zavattaro, P. Car,
G. Panzarasa, F. Prodam, P. Marzullo &
Gianluca Aimaretti**

Hormones

International Journal of Endocrinology
and Metabolism

ISSN 1109-3099

Hormones

DOI 10.1007/s42000-018-0082-9



Your article is protected by copyright and all rights are held exclusively by Hellenic Endocrine Society. This e-offprint is for personal use only and shall not be self-archived in electronic repositories. If you wish to self-archive your article, please use the accepted manuscript version for posting on your own website. You may further deposit the accepted manuscript version in any repository, provided it is only made publicly available 12 months after official publication or later and provided acknowledgement is given to the original source of publication and a link is inserted to the published article on Springer's website. The link must be accompanied by the following text: "The final publication is available at link.springer.com".



Transsphenoidal surgery for pituitary adenomas: early results from a single center

I. Karamouzis¹ · M. Caputo¹ · C. Mele¹ · A. Nuzzo¹ · M. Zavattaro¹ · P. Car² · G. Panzarasa² · F. Prodam¹ · P. Marzullo¹ · Gianluca Aimaretti¹

Received: 24 July 2018 / Accepted: 1 November 2018

© Hellenic Endocrine Society 2018

Abstract

Objective To evaluate early results of transsphenoidal surgery for pituitary adenomas.

Design Retrospective evaluation of 90 consecutive patients undergoing endoscopic pituitary adenoma surgery (2007–2016) at “Maggiore della Carità” Hospital in Novara, Italy. Age at diagnosis, sex, symptoms at presentation, hormonal and radiological data, complications of surgery, and short-term follow-up information were collected.

Results The majority of patients were male (M/F: 1.5/1, mean age at diagnosis 62.1 ± 1.5 years mean \pm SEM). Most patients (91.1%) presented with a macroadenoma ($27.4 \text{ mm} \pm 1.1 \text{ mm}$ mean \pm SEM), while 77.8% were non-functioning pituitary adenomas. Clinical presentations related to mass effect were visual impairment (74.0%) and/or hypopituitarism (55.1%). The main surgery complication was insipidus diabetes (12.2%), followed by cerebral hemorrhage (4.4%), cerebrospinal fluid (CSF) leaks (4.4%), syndrome of inappropriate antidiuresis (SIAD) (2.2%), and epistaxis (2.2%); only one patient died because of stroke. Risk of complications was not associated with tumor size (OR = 0.588, 95% CI 0.967–1.081, $p = 0.443$). Visual function improved in 70.6% of patients, while recovery of normal pituitary function occurred in 48.1%. Early neuroimaging studies demonstrated no residual tumor in 27.6% of patients. Invasion of cavernous sinus (OR = 3.293, 95% CI 0.897–16.738, $p = 0.05$) and maximum tumor diameter (OR = 6.857, 95% CI 1.039–1.309, $p < 0.01$) were associated with an unfavorable surgical outcome.

Conclusions Transsphenoidal endoscopic surgery for pituitary adenomas is safe and is frequently followed by improvement in visual symptoms, whereas recovery of pituitary function is less common. In our patients, complete surgical removal of adenomas is comparable to that of other series, but further investigations will be necessary to clarify the long-term risk of tumor recurrence.

Keywords Pituitary adenoma · Transsphenoidal surgery · Complications

Introduction

Pituitary adenomas are benign epithelial tumors that arise from adenohypophysial cells and constitute the most common lesions in the hypothalamic/pituitary region, representing ~ 10–20% of all intracranial tumors. Pituitary adenomas are broadly classified into hormone-active tumors, which cause specific clinical syndromes due to hormone hypersecretion, and non-functioning pituitary adenomas (NFPAs) [1].

The management of choice for patients with pituitary adenomas is neurosurgery, with the goal of complete tumor removal with preservation of the pituitary gland. In the late 1960s, pituitary surgery evolved from a craniotomy approach toward less invasive approaches, in particular microscopic and endoscopic. The transsphenoidal route is a direct and minimally invasive extracerebral approach to the sellar region and, therefore, it is the most widely used technique for interventions involving this area [2].

The endoscopic technique allows dynamic panoramic views, while angled scopes facilitate identification of the parasellar extensions not visualized by the microscope [3]. The advantages of this technique are minimal postoperative discomfort, lower complication rate, quick postoperative recovery rate, short hospital stay, and efficacy [4–6].

✉ Gianluca Aimaretti
gianluca.aimaretti@med.uniupo.it

¹ Endocrinology, Department of Translational Medicine, Università del Piemonte Orientale, Via Solaroli 17, 28100 Novara, Italy

² Neurosurgery, AOU “Maggiore della Carità” Hospital, Novara, Italy

Among the serious postoperative complications reported after endoscopic transsphenoidal surgery, cerebrospinal fluid leak is the most common, ranging from 1 to 6% of cases [2, 4, 7]. Operative mortalities, postoperative hemorrhages, and meningitis are rare, reported in less than 1% of cases [8, 9].

The aim of the present study was to evaluate retrospectively the clinical features and the pathohistological classification of pituitary adenomas treated via endoscopic transsphenoidal neurosurgery in our Hospital, analyzing the postoperative complications of the endoscopic transsphenoidal approach, and evaluating the clinical outcome and their course to short-term follow-up.

Patients and methods

Patients

Between 2007 and 2016, data from 90 patients who underwent a transnasal transsphenoidal endoscopic resection for pituitary adenoma presenting to the Division of Neurosurgery of the University Hospital “Maggiore della Carità” in Novara, Italy, were retrospectively collected.

Patients were enrolled in this study based on the following criteria: (i) imaging features suggestive of pituitary adenoma, (ii) absence or presence of any biochemical and clinical evidence of hormonal excess, and (iii) at least one sequential magnetic resonance imaging (MRI) during the follow-up. In the entire population, endocrinological, ophthalmological, and neuroradiological examinations that took place before and after surgery were considered. Demographic assessment at the time of the operation was collected. Moreover, hormonal data, MRI, and visual field at diagnosis were retrospectively recorded. Postoperative complications and short-term follow-up data were collected. Specifically, short-term follow-up information was obtained by hormonal evaluation on the third day, and 1 and 3 months after surgery, while MRI and ophthalmological evaluation were performed 1 and 3 months after surgery.

The study protocol was approved by local ethics committee and written informed consent was obtained from all subjects.

Methods

Hormonal evaluation

Laboratory data were obtained from the hospital central laboratory. Hormonal evaluation included cortisol, corticotropin (ACTH), free thyroxine (FT4), thyrotropin (TSH), prolactin (PRL), growth hormone (GH), insulin-like growth factor (IGF-I), luteinizing hormone (LH), follicle-stimulating hormone (FSH), testosterone (in males), and estradiol (in females).

A diagnosis of hypogonadotropic hypogonadism was reached in premenopausal women with amenorrhea, low estradiol, and low-normal gonadotropin levels, and in men with subnormal testosterone levels and low-normal gonadotropin levels. Secondary hypothyroidism was diagnosed in patients with low FT4 levels and normal or low TSH concentration. Secondary hypoadrenalism was diagnosed in patients with low morning cortisol levels below 10 µg/dL associated with a cortisol peak below 18 µg/dL in the short Synacthen test or ITT and/or clinical symptoms of hypoadrenalism that improved with replacement therapy with glucocorticoids. Hyperprolactinemia was defined as a PRL level > 20 ng/mL in women and > 15 ng/mL in men. Permanent diabetes insipidus was diagnosed when hypotonic polyuria (> 40 mL/kg body weight daily) ensued soon after surgery and lasted for 2 months. GH deficiency was defined by insufficient rise in GH levels after stimulation either during the GHRH-arginine test or during an insulin tolerance test (ITT) [10–12].

Neuroradiological evaluation

The tumor size was usually evaluated by MRI of the pituitary fossa and, when this was contraindicated, by computer tomography (CT) scan. The MRI included focused T1-weighted sagittal and coronal views and T2-weighted axial scans using a 0.5–1.5 T scanner depending on the study period. All scans were reviewed by an expert neuroradiologist blinded to the data of the study. Tumors were considered invasive of the cavernous sinus if they corresponded to grade 3 or grade 4 in the classification of Knosp and coworkers [13]. Tumors intraoperatively observed to be invading the sellar floor were considered invasive of the sphenoid sinus.

Recurrence was defined as the appearance of an apparently completely resected pituitary tumor (no visible remnant on first postoperative imaging) or regrowth of a surgical remnant (more than 2-mm increase).

Ophthalmological evaluation

Evaluation of visual function was obtained by the assessment of visual acuity and visual field using a Goldmann perimeter.

Surgical procedure and histological analysis

The surgical procedures were performed in all patients by a neurosurgeon together with an otorhinolaryngologist using transnasal transsphenoidal endoscopic surgery.

Hematoxylin and eosin-stained sections were used for histopathological diagnosis. Standard immunocytochemistry employing commercially available antisera was applied to characterize neoplastic areas for the presence of PRL, growth hormone (GH), ACTH, TSH, LH, and FSH.

Statistical analysis

The results were expressed as mean ± standard error of the mean (SEM) or percentage. Multivariate logistic regression was used in the cases of hypopituitarism and unfavorable tumor size (outcomes) to investigate possible covariates and factors associated with them. Continuous variables were analyzed using Student's *t* test. Chi-square was used to identify significant associations between variables of interest. *p* values less than 0.05 were considered significant. The dependent variables were hypopituitarism and unfavorable tumor size. The independent variables were the tumor characteristics or complications, evaluated separately. The analyses were performed using SPSS 21.0 (SPSS Inc., Chicago, Ill., USA).

Results

Preoperative evaluation

Most of the patients were male (M/F: 1.5/1) and mean age at diagnosis (mean ± SEM) was 62.1 ± 1.5 years (range 22–82 years).

Most of the patients (91.1%) presented with a macroadenoma (maximum diameter mean ± SEM: 27.4 ± 1.1 mm). NFPAs were 77.8% (*N* = 70) of the total series, while the remaining 22.2% were hormone-secreting adenomas (62.5% GH-, 25% ACTH-, 12.5% PRL-secreting adenomas resistant to medical treatment). Pathological features of these tumors at diagnosis are presented in Table 1 and are stratified as functioning and non-functioning adenomas. Clinical presentation of NFPAs was related to mass effect as visual impairment in 74.0% of cases. Invasion of the cavernous sinus was present in 74.2% of patients, the invasion of sphenoidal sinus in 40.9%, the suprasellar extension in 51.5% of cases, and at least one type of invasion was present in 90.9% of

NFPAs. As expected, the mean diameter was associated with the risk of visual defects at diagnosis (OR = 4.304, *p* = 0.025).

Pituitary hormone deficits attributed to the pituitary lesion were detected in 55.1% of cases and replacement therapy according to the clinical guidelines [14] was prescribed, as shown in Fig. 1.

Tumor diameter, extrasellar extension, and sinus invasions were statistically associated with the presence of hypopituitarism at diagnosis (OR = 3.688, *p* = 0.05; OR = 3.365, *p* = 0.005, respectively).

Surgical complications

The most frequent surgical complication was diabetes insipidus (12.2%), 11.1 and 1.1% transient and permanent, respectively, followed by cerebral hemorrhage (4.4%), cerebra-spinal fluid (CSF) rhinorrhea (4.4%), syndrome of inappropriate antidiuresis (SIAD) (2.2%), and epistaxis (2.2%) (Table 2). Risk of intraoperative complications was not statistically associated with tumor size (OR = 0.588, *p* = 0.443).

Early postoperative results

Visual function improved in 70.6% of patients who presented visual defects at diagnosis, while recovery of normal gonadal, thyroid, or adrenal function occurred in 48.1% of cases.

Postoperative hypopituitarism was present in 55.7% of cases, as shown in Fig. 2. Considering only patients with normal pituitary function before surgery, postoperative worsening of gonadal, thyroid, or adrenal function occurred in 29.2% of patients.

The risk of hypopituitarism was statistically associated with invasive tumor (OR = 3.869, *p* = 0.042), but not with tumor size and not with the presence of surgery complications (OR = 2.087, *p* = 0.201).

Table 1 Preoperative pathological features of NFPA and FPA patients

	NFPAs			FPAs		
	<i>N</i>	%	95% CI	<i>N</i>	%	95% CI
Macroadenoma	66/70	94.30	86.21–97.76	16/20	80	58.40–91.93
Previous pituitary surgery	6/64	9.4	4.37–18.98	0/20	0	0.00–16.11
Visual symptoms	37/50	74	60.45–84.13	4/18	22.2	9.00–45.21
IperPRL	12/33	36.4	22.19–53.38	5/20	25	11.19–46.87
Hypopituitarism	27/49	55.1	41.32–68.15	4/18	22.2	9.00–45.21
Invasivity	60/66	90.9	81.55–95.77	13/20	65	43.29–81.88
Suprasellar extension	34/66	51.5	39.71–63.15	4/20	20	8.07–41.60
Cavernosus sinus invasion	49/66	74.2	62.57–83.25	13/20	65	43.29–81.88
Sphenoidal sinus invasion	27/66	40.9	29.87–52.95	5/20	25	11.19–46.87

Data are presented as absolute and relative (%) frequencies

NFPAs, non-functioning pituitary adenomas; FPAs, functioning pituitary adenomas; PRL, prolactinemia; CI, confidence interval

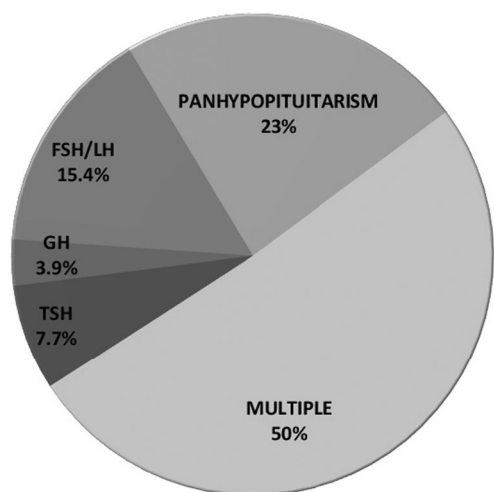


Fig. 1 Frequency of preoperative hypopituitarism in NFPAs. *Multiple*: presence of two or more pituitary deficits, excluding panhypopituitarism

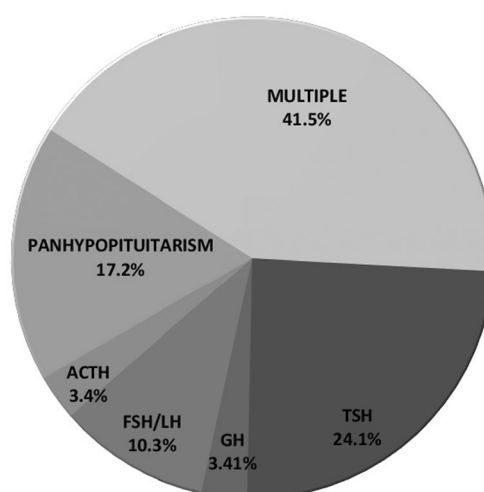


Fig. 2 Postsurgical hypopituitarism. *Multiple*: presence of two or more pituitary deficits, excluding panhypopituitarism

Surgical outcome

The first postoperative neuroimaging studies demonstrated residual tumor in 72.4% of cases (mean size 10.3 ± 2 mm), whereas no tumor residue was documented in 27.6% of patients.

Multivariate logistic regression analysis showed that tumor invasion of the cavernous sinus (OR = 3.293, $p = 0.05$) and maximum tumor diameter (OR = 6.857, $p = 0.002$) were associated with an unfavorable surgical outcome.

Discussion

The aim of surgical treatment of pituitary adenoma is to reverse endocrine dysfunction and/or resolve the compressive symptoms, with preservation of normal pituitary function. The introduction of the endoscopic approach improved surgical visualization, leading to a greater extent of resection with improved safety [4–6].

In our series of patients who underwent transsphenoidal surgery, low rates of perioperative mortality and major complications (4.4%) were reported, except for cerebral hemorrhage, probably due to the very large size of the treated lesions (4.4%). However, our results are likely similar to those described by other pituitary surgical teams [9, 15].

Postoperative hypopituitarism is a well-known complication of pituitary surgery and many patients require pituitary hormone replacement medications; however, most of these patients are able to discontinue therapy within 2 to 6 months after surgery. The reported incidence of diabetes insipidus is 0.5–15% [16–18], similar to our result (12.2%), while other series reported a lower incidence [2, 7], probably because of different definitions of this pathological condition that make it difficult to compare surgical series. Regarding anterior pituitary function, new cases of hypopituitarism occurred in approximately 29% of patients in our series; this prevalence is higher by comparison with other series [9], but the short-term follow-up of our study might not permit further validation. On

Table 2 Complications of transsphenoidal pituitary surgery

	NFPAs			FPAs			All		
	<i>N</i>	%	95% CI	<i>N</i>	%	95% CI	<i>N</i>	%	95% CI
Any complication	18/70	25.7	16.93–37.03	5/20	25	11.19–46.7	23/90	25.5	17.67–35.44
Cerebral hemorrhage	4/70	5.7	2.24–13.79	0/20	0	0.00–16.11	4/90	4.4	1.74–10.88
CSF leaks	4/70	5.7	2.24–13.79	0/20	0	0.00–16.11	4/90	4.4	1.74–10.88
Epistaxis	2/70	2.86	0.79–9.83	0/20	0	0.00–16.11	2/90	2.2	0.61–7.74
SIAD	1/70	1.4	0.25–7.66	1/20	5	0.89–23.61	2/90	2.2	0.61–7.74
Transient diabetes insipidus	7/70	10	4.93–19.23	3/20	15	5.24–36.06	10/90	11.1	6.15–19.26
Permanent diabetes insipidus	1/70	1.4	0.25–7.66	0/20	0	0.00–16.11	1/90	1.1	0.20–6.03

Data are presented as absolute and relative (%) frequencies

NFPAs, non-functioning pituitary adenomas; FPAs, functioning pituitary adenomas; CSF, cerebrospinal fluid; SIAD, syndrome of inappropriate antidiuresis; CI, confidence interval

the other hand, in the case of hypopituitarism secondary to the pituitary adenoma, surgical removal could restore pituitary hormonal function [19, 20], as confirmed in 48.1% of our patients with impaired preoperative function. Similar results were reported by different authors [9], whereas others have reported either no improvement [16, 21] or even a worsening of pituitary function [22]. Some authors speculated that improved visualization of the normal pituitary gland during endoscopic surgery may allow better preservation of the remaining gland and lead to improved functional outcomes [3].

It is well known that progressive visual impairment is a hallmark symptom of pituitary adenomas when growth extends into the suprasellar space and causes compression of the optic chiasm. Our findings showed that visual function improved after surgery in 70.6% of our patients, thus confirming the results reported by other authors [19, 23]. This is probably related to the use of the transsphenoidal approach, which causes less trauma to the optic pathway than the transcranial route. However, few cases of postsurgery visual impairment seem to be related to surgical hemorrhagic complications [8].

We achieved apparent complete surgical removal of the tumor in approximately 30% of our patients. In a large series by Losa et al., the authors reported complete tumor removal in 63% of 491 patients [9]. Frank et al. reported a total resection of 77% of their 173 cases [2]. The surgical outcomes achieved in smaller series seem less favorable, ranging from 14.3 to 43.1% [22–26], similar to our findings. The clinical features which seem to negatively affect the surgical outcome in multivariate analysis were cavernous sinus invasion and increasing maximum tumor diameter. Invasion of the cavernous sinus was also reported as the strongest independent negative predictor of complete surgical removal in another study that used multivariate analysis [26] and was confirmed by Losa et al. [9].

In conclusion, the rates of gross tumor removal, although as yet not sufficiently high, resolution of hormonal hypersecretion, and improvement in visual symptoms confirm the effectiveness of endoscopic pituitary surgery. The safety of the procedure is similarly supported by the low reported incidence of complications.

Compliance with ethical standards

The study protocol was approved by local ethics committee and written informed consent was obtained from all subjects.

Conflict of interest The authors declare that they have no conflict of interest.

Publisher's Note Springer Nature remains neutral with regard to jurisdictional claims in published maps and institutional affiliations.

References

1. Kovacs K, Scheithauer BW, Horvath E, Lloyd RV (1996) The World Health Organization classification of adenohypophysial neoplasms. A proposed five-tier scheme. *Cancer* 78:502–510
2. Frank G, Pasquini E, Farneti G et al (2006) The endoscopic versus the traditional approach in pituitary surgery. *Neuroendocrinology* 83(3–4):240–248
3. Dallapiazza RF, Jane JA Jr (2015) Outcomes of endoscopic transsphenoidal pituitary surgery. *Endocrinol Metab Clin N Am* 44(1):105–115
4. Jho HD, Carrau RL (1997) Endoscopic endonasal transsphenoidal surgery: experience with 50 patients. *J Neurosurg* 87:44–51
5. Cappabianca P, Alfieri A, de Divitiis E (1998) Endoscopic endonasal transsphenoidal approach to the sella: towards functional endoscopic pituitary surgery (FEPS). *Minim Invas Neurosurg* 41: 66–73
6. de Divitiis E, Cappabianca P, Cavallo M (2003) Endoscopic endonasal transsphenoidal approach to the sellar region. In: de Divitiis E, Cappabianca P (eds) *Endoscopic endonasal transsphenoidal surgery*. Springer, Wien, pp 91–130
7. Dehdashti AR, Ganna A, Karabatsou K et al (2008) Pure endoscopic endonasal approach for pituitary adenomas: early surgical results in 200 patients and comparison with previous microsurgical series. *Neurosurgery* 62(5):1006–1015
8. Cappabianca P, Cavallo LM, Colao A et al (2002) Surgical complications associated with the endoscopic endonasal transsphenoidal approach for pituitary adenomas. *J Neurosurg* 97(2):293–298
9. Losa M, Mortini P, Barzaghi R et al (2008) Early results of surgery in patients with nonfunctioning pituitary adenoma and analysis of the risk of tumor recurrence. *J Neurosurg* 108(3):525–532
10. Schneider HJ, Aimaretti G, Kreitschmann-Andermahr I, Stalla GK, Ghigo E (2007) Hypopituitarism. *Lancet* 369(9571):1461–1470
11. Molitch ME, Clemmons DR, Malozowski S, Merriam GR, Vance ML (2011) Evaluation and treatment of adult growth hormone deficiency: an Endocrine Society clinical practice guideline. *J Clin Endocrinol Metab* 96:1587–1609
12. Tanriverdi F, Kelestimur F (2017) Classical and non-classical causes of GH deficiency in adults. *Best Pract Res Clin Endocrinol Metab* 31(1):3–11
13. Knosp E, Steiner E, Kitz K, Matula C (1993) Pituitary adenomas with invasion of the cavernous sinus space: a magnetic resonance imaging classification compared with surgical findings. *Neurosurgery* 33:610–618
14. Fleseriu M, Hashim IA, Karavitaki N et al (2016) Hormonal replacement in hypopituitarism in adults: an Endocrine Society clinical practice guideline. *J Clin Endocrinol Metab* 101(11):3888–3921
15. Shou XF, Li SQ, Wang YF, Zhao Y, Jia PF, Zhou LF (2005) Treatment of pituitary adenomas with a transsphenoidal approach. *Neurosurgery* 56:249–256
16. Black PM, Zervas NT, Candia GL (1987) Incidence and management of complications of transsphenoidal operation for pituitary adenomas. *Neurosurgery* 20:920–924
17. Ciric I, Ragin A, Baumgartner C, Pierce D (1997) Complications of transsphenoidal surgery: results of a national survey, review of the literature, and personal experience. *Neurosurgery* 40:225–236
18. Barker FG II, Klibanski A, Swearingen B (2003) Transsphenoidal surgery for pituitary tumors in the United States, 1996–2000: mortality, morbidity, and the effects of hospital and surgeon volume. *J Clin Endocrinol Metab* 88:4709–4719
19. Arafah BM (1986) Reversible hypopituitarism in patients with large nonfunctioning pituitary adenomas. *J Clin Endocrinol Metab* 62: 1173–1179

20. Webb SM, Rigla M, Wagner A, Oliver B, Bartumeus F (1999) Recovery of hypopituitarism after neurosurgical treatment of pituitary adenomas. *J Clin Endocrinol Metab* 84:3696–3700
21. Wichers-Rother M, Hoven S, Kristof RA, Bliesener N, Stoffel-Wagner B (2004) Non-functioning pituitary adenomas: endocrinological and clinical outcome after transsphenoidal and transcranial surgery. *Exp Clin Endocrinol Diabetes* 112:323–327
22. Dekkers OM, Pereira AM, Roelfsema F et al (2006) Observation alone after transsphenoidal surgery for nonfunctioning pituitary macroadenoma. *J Clin Endocrinol Metab* 91:1796–1180
23. Colao A, Cerbone G, Cappabianca P et al (1998) Effect of surgery and radiotherapy on visual and endocrine function in nonfunctioning pituitary adenomas. *J Endocrinol Investig* 21:284–290
24. Woollons AC, Hunn MK, Rajapakse YR et al (2000) Non-functioning pituitary adenomas: indications for postoperative radiotherapy. *Clin Endocrinol* 53:713–717
25. Soto-Ares G, Cortet-Rudelli C, Assaker R et al (2002) MRI protocol technique in the optimal therapeutic strategy of non-functioning pituitary adenomas. *Eur J Endocrinol* 146:179–186
26. Greenman Y, Ouaknine G, Veshchev I, Reider-Groswasser II, Segev Y, Stern N (2003) Postoperative surveillance of clinically nonfunctioning pituitary macroadenomas: markers of tumor quiescence and regrowth. *Clin Endocrinol* 58:763–769