



Review

Successful delivery after surgical repair of uterine rupture at 15 weeks of gestation: case report and brief review

D. Surico^a, R. Amadori^{a,*}, A. Vigone^a, C. D'Agostino^a, M. Dessole^b, N. Surico^a^a Department of Obstetrics and Gynaecology, University of Eastern Piedmont, Novara, Italy^b Department of Surgical, Microsurgical and Medical Sciences, Gynaecological and Obstetric Clinic, University of Sassari, Sassari, Italy

ARTICLE INFO

Article history:

Received 11 February 2016

Received in revised form 15 April 2016

Accepted 19 May 2016

Keywords:

Uterine rupture in pregnancy

Uterine repair in pregnancy

Uterine scar in pregnancy

Midtrimester uterine rupture

Haemoperitoneum in pregnancy

ABSTRACT

Objective: Second-trimester uterine rupture is a rare disorder and it is unclear if it should be managed with caesarean section, repair or hysterectomy. This article provides a case report of second-trimester uterine rupture repair, and reviews the risk factors, signs and symptoms, suturing technique and newborn outcome.

Methods: PubMed was searched using the terms 'uterine rupture', 'second trimester' and 'repair' Only cases of second-trimester uterine rupture repair that led to successful prolongation of pregnancy were included.

Results: The main risk factor of uterine rupture is previous caesarean section (5/10, 50%). Eight of 10 cases presented with abdominal pain and three cases presented in shock. Haemoperitoneum was present in five cases. The mean and median gestational age at delivery were 33.4 and 33.5 weeks, respectively (range 28–37 weeks), with mean and median delayed interval delivery of 95.5 and 91 days, respectively (range 14–147 days). Neonatal outcome was good for 10 of 11 newborns. Despite the early onset of uterine rupture, there were no cases of extremely preterm delivery. One early preterm infant, seven moderate-to-late preterm infants and one term infant were delivered.

Conclusions: The lack of extremely preterm deliveries and good neonatal outcomes encourage attempts to repair the uterus after second-trimester rupture.

© 2016 Elsevier Ireland Ltd. All rights reserved.

Contents

Introduction	5
Case report	6
Brief review	6
Comment	6
Conflict of interest	7
Funding	7
References	7

Introduction

Rupture of the pregnant uterus is a rare disorder that occurs in less than 0.05% of pregnancies [1]. Reports of spontaneous uterine

rupture in the early trimesters are rare [2]. Uterine rupture caused by separation of the uterine myometrium is a life-threatening condition for the mother and foetus. Complete uterine rupture cannot usually be predicted and occurs suddenly during labour or delivery. During the pre-viable period, it is not known whether caesarean section, uterine repair or hysterectomy represents the best approach [3].

This article reports a case of uterine rupture that occurred during the early second trimester. Repair of the rupture site using uterine suturing led to successful prolongation of pregnancy.

* Corresponding author at: Department of Obstetrics and Gynaecology, 'Maggiore della Carita' Hospital, Viale Mazzini 18, 28100 Novara, Italy.

Tel.: +39 0321 3733665; fax: +39 0321 3733659.

E-mail address: ierama@tin.it (R. Amadori).

Case report

A 40-year-old Russian woman (gravida 2, para 1) was referred to the authors' hospital with progressive abdominal pain at 15 + 5 weeks of gestation. Her first pregnancy had resulted in preterm caesarean delivery at 27 weeks of gestation for placental abruption, leading to stillbirth. She denied abdominal trauma, fever, nausea, anorexia, vomiting or vaginal bleeding. Up to that point, her current pregnancy had been uneventful. She had conceived naturally, without any assisted reproductive treatment. A previous second-trimester ultrasound had normal results.

At admission, her vital signs were normal with blood pressure of 110/60 mmHg and pulse of 66 beats/min. Haematocrit was 34.8%, haemoglobin was 12.3 g/dl and white blood cell count was 9500/ μ l. On abdominal examination, she reported pain in the entire abdomen; the pain was stronger around the right hypochondriac region with rebound tenderness. Bowel sounds were audible but weak. Pelvic examination showed normal secretions, no vaginal bleeding and no cervical dilation. Her cervix was closed, thick, firm and posterior. Transvaginal ultrasonography revealed a regular cervical length (39 mm) without funnelling, no fluid collection in the cul-de-sac space, and a single intrauterine pregnancy with positive foetal heart activity. The placenta was located on the anterior uterine wall above the lower uterine segment. Other organs, including the kidneys, gallbladder and liver, were sonographically normal. Over the 3 h following admission, her symptoms gradually worsened and haemoglobin decreased to 8.5 g/dl. An additional ultrasound examination revealed echo-free space in the vesico-uterine pouch, suggesting haemoperitoneum and a foetus with cardiac activity. The initial diagnosis was appendicitis or ovarian torsion, so exploratory laparoscopy was performed. Before the medical procedure, the patient was advised about the potential risks and benefits of the intervention, and she gave her informed consent. Haemoperitoneum (1000 g of blood loss) was found with a myometrial defect on the anterior uterine wall. Uterine rupture with complete opening of the uterine wall at the site of the previous transverse scar was found, with protrusion of the placenta. Conversion to open surgery was necessary. The ruptured uterus was repaired using two-layered separate stitch sutures of 1-0 polyglactin 910 (Coated Vicryl, Ethicon, Inc., Somerville, NJ, USA) (Fig. 1). The patient's postoperative recovery was uneventful and she was discharged on the fifth postoperative day. She was informed of the potential risks of this conservative management and was discharged home. A healthy baby (weight 2640 g, normal Apgar scores) was delivered by elective traditional caesarean section because of placenta praevia at 36 weeks of gestation.

Brief review

PubMed was searched using the terms 'uterine rupture', 'second trimester' and 'repair' [4]. Thirty-seven articles were checked and nine documents were extracted [5–13]. Data are summarized in Tables 1 and 2.

The main risk factor for uterine rupture was previous caesarean section (5/10, 50%), but uterine rupture also occurred in the absence of risk factors in three cases (30%). One patient had experienced uterine rupture previously. Nine patients had a singleton pregnancy (90%) and five patients were primiparae. Maternal age ranged from 28 to 40 years (mean 31.6, median 30.5 years). The mean and median onset of uterine rupture were 19.8 and 20 weeks, respectively (range 13–26).

In 60% of patients (6/10), there were no detectable ultrasound patterns. Eight patients presented to the emergency room with abdominal pain and three patients presented in shock. Haemoperitoneum was present in five patients. Fever and vaginal

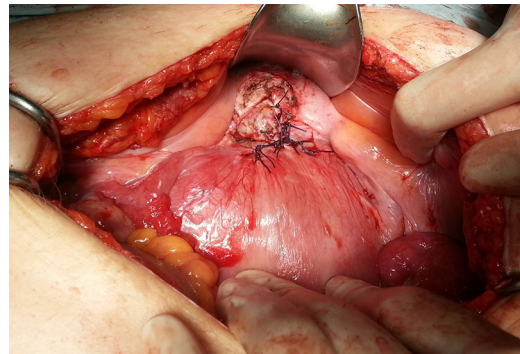


Fig. 1. Uterine repair.

bleeding were detected in one patient, and vomiting was absent in all patients. Two patients had foetal tachycardia.

The uterine suture was made by single-layered stitches, two-layered stitches and three-layered stitches in five, four cases and one patients, respectively; no differences were found between these techniques in terms of maternal and foetal outcomes. Mean and median gestational age at delivery were 33.4 and 33.5 weeks, respectively (range 28–37 weeks), with mean and median delayed interval delivery of 95.5 and 91 days, respectively (range 14–147). Sixty-percent of patients had an elective caesarean section, and the remaining 40% had an emergency caesarean section. No patients underwent hysterectomy. The neonatal outcome was good for 10 of the 11 newborns (one twin died postpartum). Despite the early onset of uterine rupture, there were no cases of extremely preterm delivery. One early preterm infant, seven moderate-to-late preterm infants and one term infant were delivered.

Comment

Several reports have been published regarding repair of uterine rupture in the second trimester by suturing and/or patching [14]. The subsequent pregnancy outcome after conservative management of uterine rupture was only been studied in small case series, among which the prevalence of recurrence ranged from approximately 0 to 33% [15].

Risk factors for third-trimester uterine rupture in labour are well known; nevertheless, data on spontaneous second- and early third-trimester uterine rupture before labour remain very limited [16]. This brief review identified a previous caesarean section as the main risk factor for uterine rupture [17]. However, three of the 10 cases of uterine rupture had no demonstrable risk factors. Rupture of the unscarred pregnant uterus is a rare event, estimated to occur in one in 5700 to one in 20,000 pregnancies [18]. Unscarred uterine rupture is a rare event that usually occurs in late pregnancy or during labour. Risk factors for this condition include high parity, placental abnormalities and uterine anomaly, but none of these factors were present in this series. Although rare, primary uterine rupture is particularly morbid [19,20]. Uterine rupture can occur at any time during gestation and may be difficult to predict [21]. Therefore, uterine rupture must be considered in differential diagnoses of severe abdominal pain, even in the early second trimester.

Clinical signs of uterine rupture in early pregnancy are non-specific and must be distinguished from acute abdominal emergencies.

Abdominal pain, vaginal bleeding and vomiting are classic findings [22]. This brief review detected abdominal pain as the only main clinical sign, not necessarily associated with acute abdomen or haemoperitoneum. The pain was non-specific and began hours

Table 1

Literature review of uterine rupture during the second trimester of pregnancy with surgical repair and successful outcome.

Case	Age (GW)	G/P	Onset (GW)	Scarred uterus	Repair	CS (GW)	Interval delivery (days)	Onset of delivery	Newborn survival
1	40	2/1	15	One previous preterm CS, placenta praevia	Two-layered separate stitches suture of 1–0 polyglactin 910	36	147	Elective	Yes
2	28	3/2	14	Two previous CS	Three-layered separate stitches suture of 3–0 polyglactin 910, patched by TachoComb	34	141	Elective	Yes
3	35	2/0	19	Previous uterine rupture	Sutured with chromic catgut and Ethibond, patched by GoreTex	33	98	Elective	Yes
4	35	3/2	20	Two previous CS (one preterm)	Sutured with 5–0 Vicryl, patched by semisynthetic Vicryl Mesh and Surgicel fibrillar	32	84	Elective	Yes
5	31	1/0	21	No	Two-layer suture with 1–0 Monocryl, single-layer suture with 3–0 Vicryl	33	84	P-PROM	Yes
6	30	1/0	24	No	Sutured with Vicryl patched by TachoComb	35	77	Pain	Yes
7	29	1/0	26	No	Continuous 1–0 chromic catgut	37	77	Elective	Yes
8	30	2/1	20	Previous postpartum evacuation of placental tissue	Two layers with 0-Vicryl suture	36	112	Elective	Yes
9	31	2/1	26	One previous CS	Imbricating running loop '0' PDS suture	28	14	Spontaneous labour	Yes
10	29	6/0	13 (twin)	Previous cornual pregnancy managed via laparoscopy	Two layers of overlapping purse string sutures, of 1–0 chromic catgut	30	121	Spontaneous labour	Twin B yes, Twin A died postpartum

GW, gestational weeks; G/P, gravida/para; CS, caesarean section; P-PROM, preterm premature rupture of membranes.

Case 1 is the case patient, Case 2 is from Sugawara et al. (2014), Case 3 is from Martin et al. (1990), Case 4 is from Palacios-Jaraquemada et al. (2009), Case 5 is from Wang et al. (1999)

Case 6 is from Shirata et al. (2007), Case 7 is from Chen (2007), Case 8 is from Fujii et al. (2000), Case 9 is from Gorthi et al. (2009), and Case 10 is from Liao et al. (2009).

Table 2

Literature review of second-trimester uterine rupture: signs and symptoms.

	Onset (GW)	Ultrasound evidence	Pain	Fever	Vomiting	Vaginal bleeding	Shock	Haemoperitoneum (g)	Foetal symptoms
1	15	No	Present	Absent	Absent	Absent	Absent	1000	Absent
2	14	No	Present	Absent	Absent	Absent	Absent	1300	Absent
3	19	Yes	Present	Absent	Absent	Absent	Absent	NA	Absent
4	20	No	Present	Absent	Absent	Absent	Present	2000	Absent
5	21	No	Present	Present	Absent	Absent	Present	3000	Tachycardia
6	24	No	Present	Absent	Absent	Absent	Present	2200	Absent
7	26	No	Present	Absent	Absent	Absent	NA	NA	Absent
8	20	Yes	Absent	Absent	Absent	Absent	Absent	Absent	Absent
9	26	Yes	Absent	Absent	Absent	Absent	Absent	Absent	Tachycardia complicated by variable decelerations
10	13	Yes	Present	Absent	Absent	Present	Absent	Absent	Absent

GW, gestational weeks; NA, not assessed.

to days prior to the diagnosis of uterine rupture. The patient in this case report was evaluated for non-obstetric diagnoses related to upper abdominal pain because she presented with minor acute signs and symptoms in addition to normal sonographic appearances of the uterus and foetus. Another issue is silent uterine rupture; this has potential risk for complete uterine rupture, which leads to acute life-threatening complications for both the mother and baby. It is difficult to determine whether to manage complete uterine rupture expectantly or surgically, including repair of the uterine wall or termination of the pregnancy, especially in the early second trimester [22].

Early correct diagnosis and proper management are necessary to decrease the high maternal and foetal mortality and morbidity rates associated with uterine rupture. An emergency laparoscopy or laparotomy is needed for correct diagnosis and to allow the appropriate treatment to take place. Early surgical intervention is usually the key to successful treatment of uterine rupture. This brief review found no differences between single-, two- and three-layered sutures on maternal and foetal outcomes, but the sample size was very small. Treatment will primarily depend on the extent of the lesion; parity, age and condition of the patient; and expertise

of the surgeon. However, this brief review found that it was possible to delay delivery in all cases, thus improving neonatal outcome. Repair of a ruptured uterus can lead to prolongation of pregnancy, and consequently yield favourable maternal and foetal/neonatal outcomes. The lack of extremely preterm deliveries and good neonatal outcomes encourage attempts to repair the uterus after second-trimester rupture.

Conflict of interest

None declared.

Funding

None.

References

- [1] Hofmeyr GJ, Say L, Gülmezoglu AM. WHO systematic review of maternal mortality and morbidity: the prevalence of uterine rupture. *BJOG* 2005;112: 1221–8.

- [2] Vaknin Z, Maymon R, Mendlovic S, Barel O, Herman A, Sherman D. Clinical, sonographic, and epidemiologic features of second- and early third-trimester spontaneous antepartum uterine rupture: a cohort study. *Prenat Diagn* 2008; 28:478–84.
- [3] Smith JF, Wax JR. Rupture of the unscarred uterus. Available at: <http://www.uptodate.com/contents/rupture-of-the-unscarred-uterus> (accessed 17.02.12).
- [4] Sugawara T, Ogawa M, Tanaka T. Repair of uterine rupture during second trimester leading to successful pregnancy outcome: case study and literature review. *AJP Rep* 2014;4:9–12.
- [5] Martin Jr JN, Brewer DW, Rush Jr LV, Martin RW, Hess LW, Morrison JC. Successful pregnancy outcome following mid-gestational uterine rupture and repair using Gore-Tex soft tissue patch. *Obstet Gynecol* 1990;75:518–21.
- [6] Palacios-Jaraquemada JM, Fiorillo A, von Petery F, Colaci D, Leguizamón G. Uterine repair and successful pregnancy after myometrial and placental rupture with massive haemoperitoneum. *BJOG* 2009;116:456–60.
- [7] Wang PH, Chao HT, Too LL, Yuan CC. Primary repair of cornual rupture occurring at 21 weeks gestation and successful pregnancy outcome. *Hum Reprod* 1999;14:1894–5.
- [8] Shirata I, Fujiwaki R, Takubo K, Shibukawa T, Sawada K. Successful continuation of pregnancy after repair of a midgestational uterine rupture with the use of a fibrin coated collagen fleece (TachoComb) in a primigravid woman with no known risk factors. *Am J Obstet Gynecol* 2007;4:e7–9.
- [9] Chen FP. Term delivery after repair of a uterine rupture during the second trimester in a previously unscarred uterus: a case report. *J Reprod Med* 2007; 52:981–3.
- [10] Fujii T, Kozuma S, Unno N, Kuwabara Y, Taketani Y. Successful pregnancy following antenatal closure of uterine wall defect. *Int J Gynecol Obstet* 2000; 68:261–2.
- [11] Gorthi S, Simpson NA, Lodge V, Dunham RJ, Lane G. Management of asymptomatic mid-trimester lower segment scar dehiscence. *Eur J Obstet Gynecol Reprod Biol* 2009;147:241–2.
- [12] Liao CY, Ding DC. Repair of uterine rupture in twin gestation after laparoscopic cornual resection. *J Minim Invasive Gynecol* 2009;16:493–5.
- [13] Kanao S, Fukuda A, Fukuda H, et al. Spontaneous uterine rupture at 15 weeks' gestation in a patient with a history of cesarean delivery after removal of shirodkar cerclage. *AJP Rep* 2014;4:1–4.
- [14] Vaknin Z, Maymon R, Mendlovic S, Barel O, Herman A, Sherman D. Clinical, sonographic, and epidemiologic features of second and early third-trimester spontaneous antepartum uterine rupture: a cohort study. *Prenat Diagn* 2008; 28:478–84.
- [15] Ofir K, Sheiner E, Levy A, Katz M, Mazor M. Uterine rupture: risk factors and pregnancy outcome. *Am J Obstet Gynecol* 2003;189:1042–6.
- [16] Zwart JJ, Richters JM, Ory F, de Vries JI, Bloemenkamp KW, van Roosmalen J. Uterine rupture in The Netherlands: a nationwide population-based cohort study. *BJOG* 2009;116:1069.
- [17] Guèye M, Mbaye M, Ndiaye-Guèye D, et al. Spontaneous uterine rupture of an unscarred uterus before labour. *Case Rep Obstet Gynecol* 2012;2012: 598356.
- [18] Gibbins KJ, Weber T, Holmgren CM, Porter TF, Varner MW, Manuck TA. Maternal and fetal morbidity associated with uterine rupture of the unscarred uterus. *J Obstet Gynecol* 2015;213:382.
- [19] Endres LK, Barnhart K. Spontaneous second trimester uterine rupture after classical cesarean. *Obstet Gynecol* 2009;6:806–8.
- [20] Ijaz S, Mahendru A, Sanderson D. Spontaneous uterine rupture during the 1st trimester: a rare but life-threatening emergency. *J Obstet Gynaecol* 2011;31: 772.
- [21] Iemura A, Kondoh E, Kawasaki K, et al. Expectant management of a herniated amniotic sac presenting as silent uterine rupture: a case report and literature review. *J Matern Fetal Neonatal Med* 2014;28:106–12.
- [22] Tola EN. First trimester spontaneous uterine rupture in a young woman with uterine anomaly. *Case Rep Obstet Gynecol* 2014;2014:967386.